

## INDICATIONS FOR SURGICAL TREATMENT OF FIBROCYSTIC CHANGES OF THE BREAST

Mihaela Avram<sup>1</sup>,  
D. Koukoulas<sup>2</sup>,  
I. Avram<sup>1</sup>,  
Ana-Maria Maxim<sup>3</sup>,  
M. Teodorescu<sup>1</sup>,  
J. Avram<sup>1</sup>,  
Alis Dema<sup>3</sup>,  
Sorina Tăban<sup>3</sup>,  
Marioara Cornianu<sup>3</sup>

**SUMMARY:** *The treatment of fibrocystic changes of the breast is various, ranging from topical drugs, to systemic therapy and surgical treatment. As the moment for surgical therapy is not well defined we have conducted a 5 years (2004-2008) retrospective study of 622 patients with fibrocystic changes of the breast admitted in the Timisoara County Clinical Emergency Hospital and we compared their characteristic with 89 patients surgically treated for fibrocystic changes in the 1st Surgery Clinic of the same hospital. We found out that the surgical treatment of fibrocystic changes (FCC) was mainly applied in younger patients, with mastalgia but also for diagnostic reasons in patients without a certain diagnosis of benignity after clinical and imagistic examinations. The concordance between the intraoperative frozen section pathological examination and the paraffin embedded pathological diagnosis, performed by The Pathology Department of SCJUT, was 100% in the 1st Surgical Clinic lot. For the FCC patients in the 1st Surgical Clinic, in the category BI-RADS 3 lesions 17,5% had breast cancer and in the category BI-RADS4 lesions 95% had breast cancer, these figures show the difficulties in diagnosing breast cancer in patients with FCC which might lead to the delay of diagnosis of breast cancer.*

**Keywords:** *fibrocystic changes, surgical treatment*

### INDICAȚIILE TRATAMENTULUI CHIRURGICAL ÎN MASTOZA FIBRO-CHISTICĂ

**Rezumat:** *Tratamentul mastozei fibrochistice este variat, de la tratament local, la terapii sistemice și tratament chirurgical. În lipsa unor ghiduri exacte de tratament momentul aplicării tratamentului chirurgical este slab definit. Am efectuat un studiu retrospectiv pe o perioadă de 5 ani (2004-2008), comparând caracteristicile a 622 paciente cu diagnosticul de mastoză fibrochistică internate în Spitalul Clinic Județean de Urgență Timișoara cu caracteristicile celor 89 de pacienți tratați chirurgical pentru mastoză fibrochistică în Clinica Chirurgie 1 a aceluiași spital. Am evidențiat faptul că tratamentul chirurgical a fost folosit la pacientele ce prezentau mai frecvent simptome algice, la paciente mai tinere dar și la pacientele la care diagnosticul de benigneitate nu era cert prin examinare clinică și imagistică. Concordanța între diagnosticul morfolopatologic extemporaneu și cel definitiv la parafina la cazurile tratate chirurgical în Clinica Chirurgie 1, a fost de 100%. În lotul de paciente din Clinica Chirurgie 1, din leziunile din categoria BI-RADS 3 -17,5% au prezentat cancer, din leziunile BI-RADS 4-95% au prezentat cancer, arătând dificultățile de diagnostic imagistic al cancerului de sân la pacientele cu mastoză fibrochistică.*

Received for publication: 14.09.2009  
Revised: 20.10.2009

1. - County Hospital Timisoara, 1st Surgery Clinic
2. - County Hospital Timisoara, Gastroenterology Clinic
3. - County Hospital Timisoara

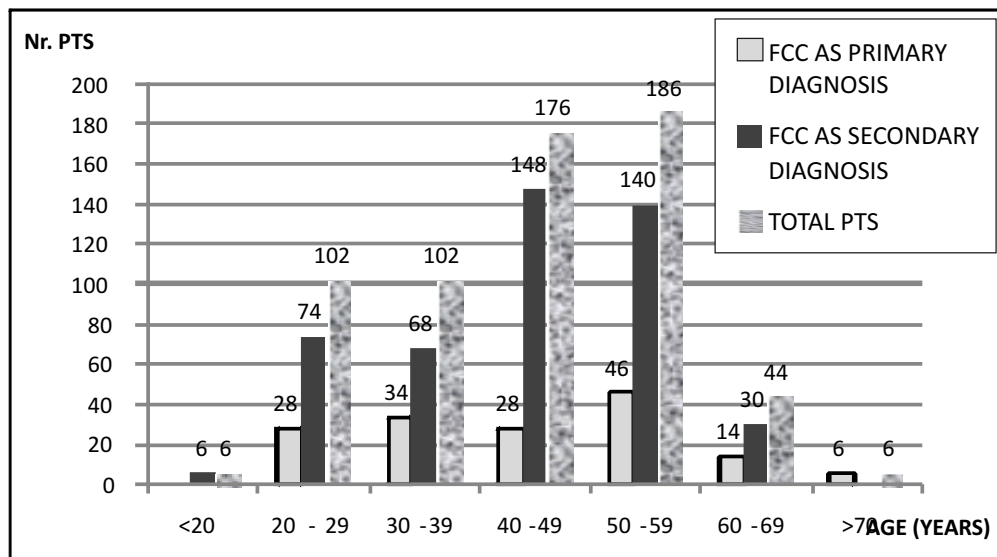


Fig. 1. Age of patients with FCC SCJUT Hospital lot

## INTRODUCTION

Fibrocystic changes of the breast (FCC) is a benign lesion that presents itself in various pathological, imagistic and clinical forms. The illness benefits of nutritional and medical treatments but the effectiveness of these therapies and the clear elimination of the menace of cancer did not reach yet “the gold standard”. In the case of malignancy suspicion or in the case of cysts that reappear or do not disappear completely after fine needle aspiration the surgical treatment is recommended. In this situation the surgery is a conservative one, limited to obtaining a tissue fragment for pathological exam, its size depending upon the clinical and imagistic aspect of the lesion. The election of the surgical method depends upon the requests of the doctors that performed the imagistic diagnostic and upon the experience of the surgeon. Mainly there are “fine needle aspiration”, “core needle biopsy” and “excisional (open) biopsy”, “lumpectomy”. We analyzed the characteristics of the patients with fibrocystic changes of the breast in order to evaluate the possible utility of this technique. By comparing patients with FCC admitted in County Hospital Timisoara over a period of 5 years with the patients treated during the same period in one surgical clinic of this hospital we aimed to establish the right time for surgical treatment of FCC.

## MATERIAL AND METHODS

A comparative retrospective study of patients with fibrocystic changes of the breast (FCC) was conducted for the patients admitted in the Timisoara County Clinical Emergency Hospital (SCJUT) in the 5 years period 2004 – 2008 and for the patients treated in the 1st Surgery Clinic

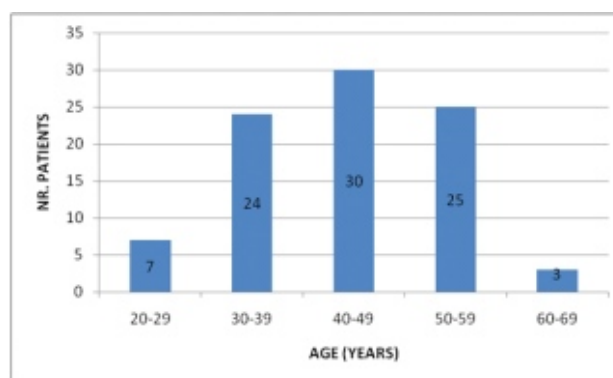


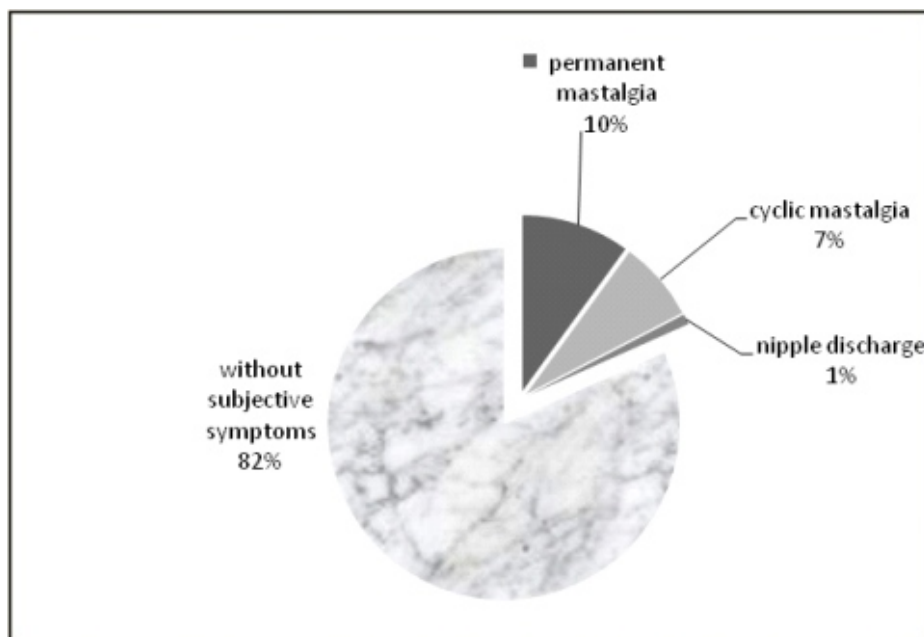
Fig. 2. Age of patients with FCC 1st Surgery Clinic lot

of the SCJUT Hospital. The study included a number of 622 female patients having the main or secondary diagnosis of FCC. 27,65% (172 cases) were treated surgically for FCC, from these, 89 were treated in the 1st Surgery Clinic.

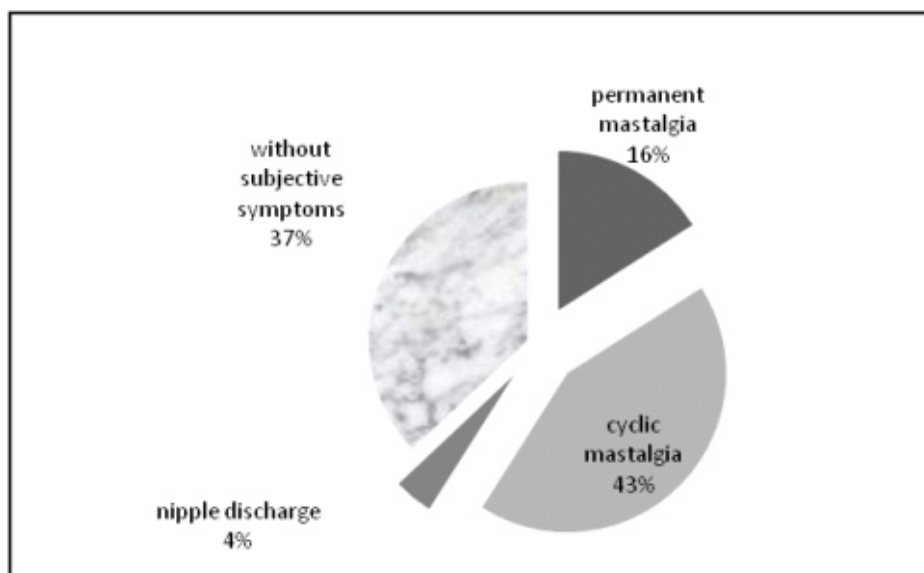
## RESULTS

By comparing the ages of all 622 patients with FCC as main and secondary diagnosis treated in SCJUT Hospital (Fig.1) with the ages of the 89 patients treated for FCC in the 1st Surgery Clinic of the SCJUT Hospital (Fig.2) we found that:

- In the SCJUT lot of patients FCC was most frequent in the 50-59 age group and the 40-49 age group, both age groups being almost equal as number
- In the 1st Surgery Clinic of the SCJUT Hospital lot FCC was more frequent in the 40-49 age group



**Fig. 3.** Subjective breast symptomatology of patients with FCC in SCJUT Hospital lot



**Fig. 4.** Subjective breast symptomatology of patients with FCC 1st Surgery Clinic Lot

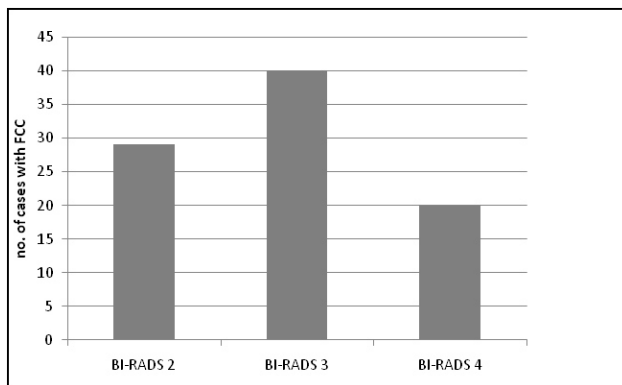
We analyzed the symptoms accused by the patients upon admittance and we found that:

- the SCJUT Hospital lot with FCC: 82% had no subjective symptoms upon admittance in the hospital, 10% accused permanent mastalgia, 7% had cyclical mastalgia and 1% presented a history of nipple discharge (Fig.3)
- the 1st Surgery Clinic lot with FCC: 37% had no subjective symptoms upon admittance in the hospital, 16% accused permanent mastalgia, 43% had cyclical mastalgia and 4% presented a history of nipple discharge (Fig.4).

In the 1st Surgery Clinic imagistic investigations of the breast were performed mainly before admittance in the

hospital. These exams were: breast ultrasound (all patients), mammography (72 patients), MRI of the breast (4 patients). The results of the imagistic exams, reported as BI-RADS (Breast Imaging Reporting and Data System) categories were (Fig.5):

- BI-RADS 0 (assessment incomplete) and BI-RADS 1 (negative) – no patients
- BI-RADS 2 – benign– 29 patients (32.58%)
- BI-RADS 3 – probably benign (<2% malignancy chance) – 40 patients (44.94%)
- BI-RADS 4 - suspicious abnormality (23%-34% malignancy chance) – 20 patients (22,47%)



**Fig.5.** Lot FCC in 1st Surgery Clinic preoperative imagistic BI-RADS classifications

- BI-RADS 5 (highly suspicious of malignancy) and BI-RADS 6 (known biopsy-proven malignancy) - no patients

The surgical treatment applied to the patients with FCC was lumpectomy or sectoral mastectomy under general i.v. anesthesia. The lesion removed was sent to frozen intraoperative pathological examination. The lesion was found to be benign in 63 patients and no further surgical treatment was performed. The result was malignancy (26 patients) mastectomy and axillary lymph node dissection was performed. The paraffin-embedded sections examinations confirmed in all cases the benign or malign characters established by the intraoperative pathological exam.

By comparing the pathological exams results with the preoperative imagistic diagnosis we observed that:

- BI-RADS 2 category -29 patients. Postoperative pathological findings: 16 were FCC and 13 associated fibroadenoma
- BI-RADS 3 category -40 patients. Postoperative pathological findings: 33 were FCC and 7 (17.5%) were FCC and breast cancer
- BI-RADS 4 category - 20 patients. Postoperative pathological findings: 1 was FCC and the other 19 (95%)were FCC and breast cancer

## DISCUSSIONS

The treatment of FCC is not well settled by guidelines. The medical treatment uses a vast arsenal of drugs in order to relieve the mastalgia as well as the lumpy consistency of the breast. The drugs used are various: topical progesterone gel (although the success rate of this therapy is not known), topical anti-inflammatory drugs which are efficient in reducing mastalgia (1) Danazol (7-alfa-etinil testosterone) which treats mastalgia and reduces the size of cysts (2), Bromocriptine which reduces mainly the breast

tenderness but does not influence the clinical symptoms(3), Oenothera Biennis extract which reduces mastalgia with 50% (4), Tamoxifene, which treats mastalgia in up to 100% cases, improves clinical features and prevents recurrence of FCC (5).

The question is when the time is and which is the place for the surgical treatment of FCC? Should it only be used as a diagnostic mean or are there times in which it is required as a treatment? Invasive diagnostic measures for FCC vary from fine needle aspiration, to open biopsy and lumpectomy. In the last years new methods were introduced for interventional treatment of FCC (Advanced Breast Biopsy Instrumentation –ABBI-and minimally Invasive Breast Biopsy -MIBB-), to guide with stereotaxic control the surgical instruments (large core needle or cannula) and even to remove lesion up to 20mm in size. Useful in nonpalpable breast lesions, the indications of these techniques are still controversial, as some of the patients who underwent these methods required further surgical treatment. Also the post interventional rate of complications is superior to the rate of complications after open surgery.(6)

In the lot we have studied we noticed that the patients who received surgical treatment were younger than those treated conservatory. This raises the question if FCC in younger patients needs to be treated surgically more often than FCC in older patients. In order to solve this problem we should also take into consideration the fact that in recent years breast cancer in women under 40 years seems to be a different entity than cancer in older women, as it has genetic and prognosis particularities. (7)

Comparing the two lots we noticed that breast pain was more frequent in women receiving surgical treatment for FCC compared to all women with FCC admitted in SCJUT Hospital, leading to the conclusion that mastalgia resistant to medical treatment determined the choice of surgical treatment.

In the 1st Surgery Clinic lot intraoperative frozen section pathological examination was performed in all cases and the diagnosis corresponded, in all cases, with the paraffin embedded pathological diagnosis. Frozen section intraoperative examination is not accepted by all for FCC, due to a lack of concordance with the paraffin embedded pathological diagnosis. (8) In our lot the concordance between the two types of diagnosis was 100% .

We also observed the fact that the rate of carcinoma in patients with FCC in 1st Surgical Clinic was greater than expected taking into consideration the BI-RADS preoperative category. This fact is probably due to the

characteristics of FCC, as the fibrosis present might imagic hide breast cancer (9).

## CONCLUSIONS

In conclusion, the surgical treatment of FCC was mainly applied in younger patients, with mastalgia but also for diagnostic reasons in patients without a certain diagnosis of benignity after clinical and imagic examinations. The concordance between the intraoperative frozen section pathological examination

and the paraffin embedded pathological diagnosis, performed by The Pathology Department of SCJUT, was 100% in the 1st Surgical Clinic lot. For the FCC patients in the 1st Surgical Clinic, in the category BI-RADS 3 lesions 17,5% had breast cancer and in the category BI-RADS4 lesions 95% had breast cancer, these figures show the difficulties in diagnosing breast cancer in patients with FCC which might lead to the delay of diagnosis of breast cancer.

### References:

1. **Irving AD, Morrison SL.** Effectiveness of topical non-steroidal anti-inflammatory drugs in the management of breast pain. *J R Coll Surg Edinb.* 1998 Jun;43(3):158-9.
2. **von Fallois J, Etterli-Billenkamp U, Schindler EM, Schindler AE.** Danazol for treatment of fibrocystic mastopathy] *Zentralbl Gynakol.* 1995;117(9):457-65.
3. **Nazli K, Syed S, Mahmood MR, Ansari F.** Controlled trial of the prolactin inhibitor bromocriptine (Parlodel) in the treatment of severe cyclical mastalgia. *Br J Clin Pract.* 1989 Sep;43(9):322-7.
4. **Singletery E., Robb G.L., Hortobagyi G.N.,** Advanced therapy of breast disease Ed.2, PMPH-USA, 2004, pg.31
5. **Tan-Chiu E, Wang J, Costantino JP, Paik S, Butch C, Wickerham DL, Fisher B, Wolmark N.** Effects of tamoxifen on benign breast disease in women at high risk for breast cancer. *J Natl Cancer Inst.* 2003 Feb 19;95(4):302-7.
6. **Tsang Flora H. F. ; Lo Giovanni J. ; Wong Joyce L. N. ; Lee Francis C. W. ; Chow Louis W. C.** Application of image-guided biopsy for impalpable breast lesions in Chinese women. *Australian and New Zealand journal of surgery.* 2003, vol. 73, no1-2, pp. 23-25
7. **I Guerra, J Algorta, R Díaz de Otazu, A Pelayo, J FariZa** Immunohistochemical prognostic index for breast cancer in young women *Mol Path* 2003;56:323-327 doi:10.1136/mp.56.6.323
8. **Stolnicu S, R[dulescu D, Plesea IE, Dobru D, Podoleanu C, Pintilei DR.** The value of intraoperative diagnosis in breast lesions. *Rom J Morphol Embryol.* 2006;47(2):119-23.
9. **You JK, Kim EK, Kwak JY, Kim MJ, Oh KK, Park BW, Yang WI.** Focal fibrosis of the breast diagnosed by a sonographically guided core biopsy of nonpalpable lesions: imaging findings and clinical relevance. *J Ultrasound Med.* 2005 Oct;24(10):1377-84.